Dallas/Fort Worth Edition

M.D. NEWS

Special Feature

Super Stim

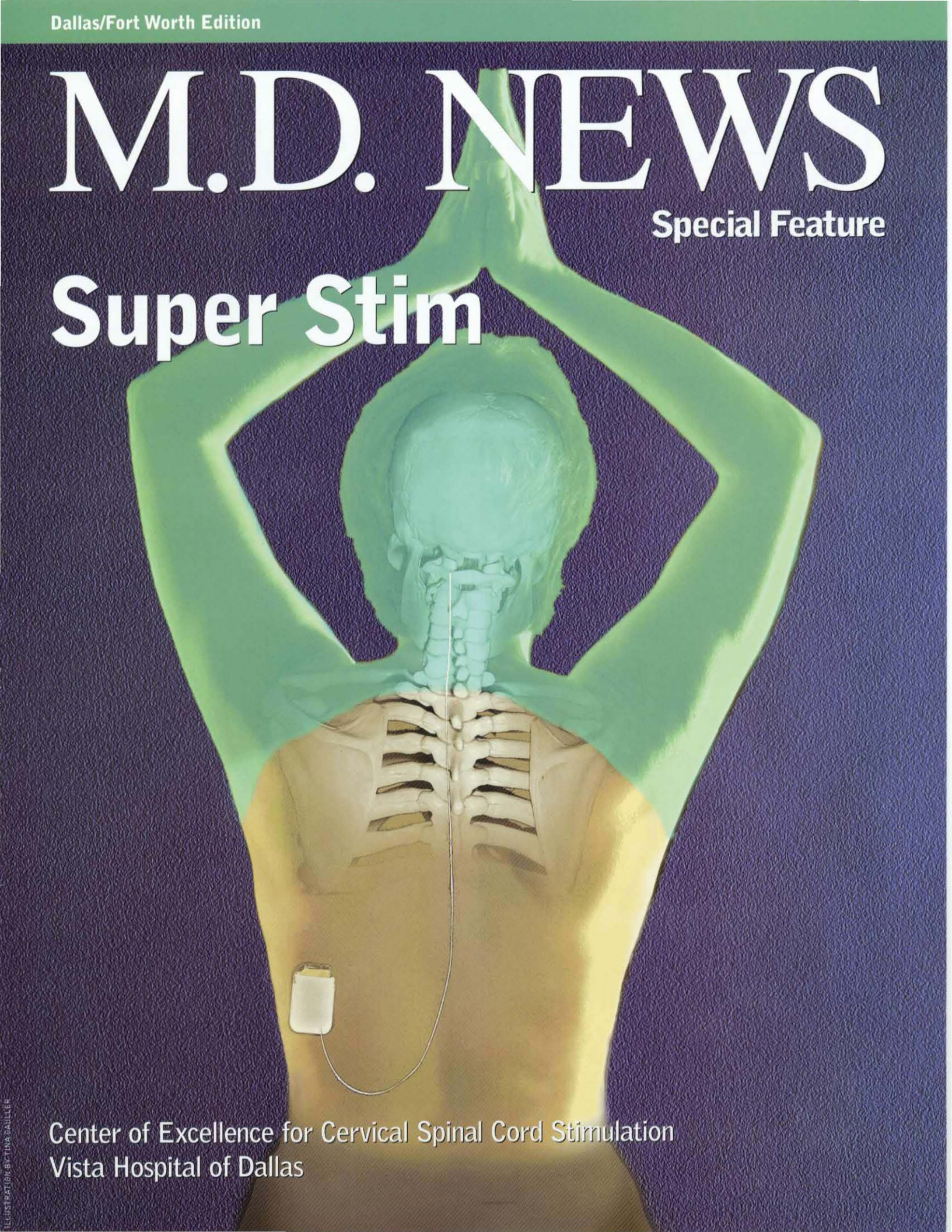

Center of Excellence for Cervical Spinal Cord Stimulation
Vista Hospital of Dallas

ILLUSTRATION: BETINA BAULLER

Treating Chronic Neck Pain

An Innovative Approach by Surgeons at Vista Hospital's Center of Excellence for Cervical Spinal Cord Stimulation

By Tina Cauller

Although therapeutic electrical stimulation of the spinal cord (SCS) to treat chronic pain conditions has been performed since the early 1970s, significant technological refinements over the last 35 years have enabled much better rates of lasting success, resulting in more widespread acceptance of pain management using SCS. Spinal cord stimulation is delivered by a small, implantable stimulator device. The stimulator sends low-level electrical impulses to the nerves, which interferes with the transmission of pain signals to the brain and replaces painful sensations with a more pleasant tingling sensation called paresthesia.

> The neck neurological "sweet spot" is difficult to access percutaneously.

For patients with midline neck pain or occipital neuralgia (occipital headaches), however, there have historically been few effective options for pain relief, and attempts to utilize SCS for treatment of these complex syndromes have been unsuccessful over the long

Pioneering efforts a decade ago by neurosurgeon Giancarlo Barolat, M.D., to address occipital or neck pain by introducing electrodes caudally under the arch of C1 and C2 successfully achieved paresthesia coverage of the painful region in about 80 percent of patients, but his cases were fraught with electrode breakage problems related to the extreme motion mechanics of the upper spine. Since nearly 50 percent of flexion and extension occurs at occiput-C1 and 50 percent of rotation at C1-C2, flat paddle lamitrodes, which were held firmly in position by post-surgical scarring, were vulnerable to malfunction and eventual breakage. Subsequent attempts to approach from under C3 going cephaled to C1-C2 with paddle leads met with slightly better success, but the paddle electrodes still tended to fail over time.

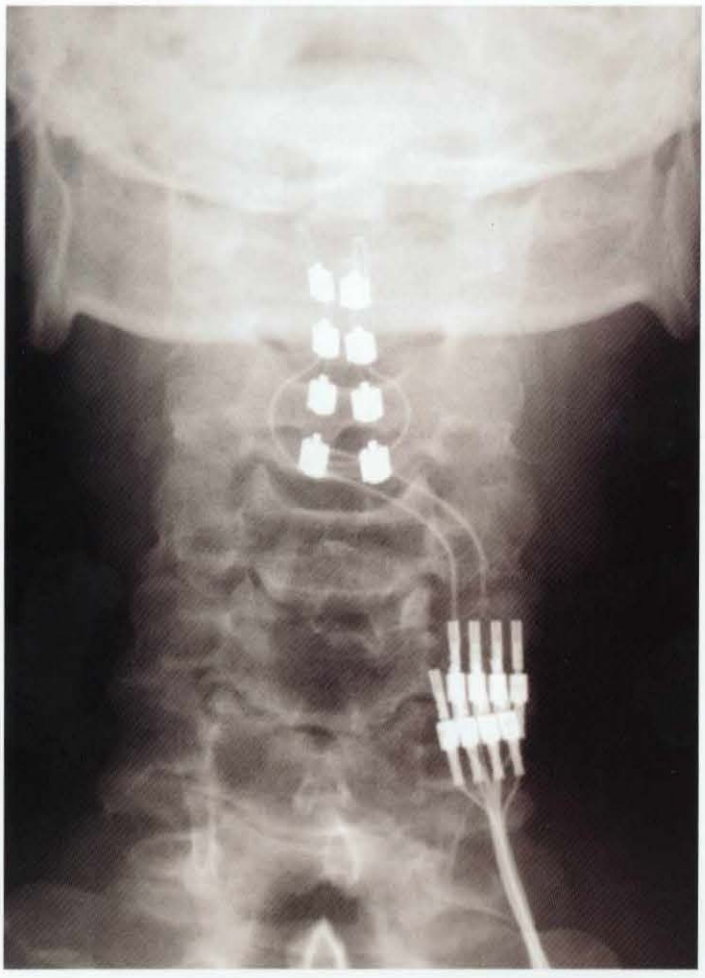



PHOTOS BY STEVE GALLEGOS, LONESTAR PHOTOGRAPHY STUDIOS, 214-452-7780



The neck neurological "sweet spot" first identified by Dr. Barolat is difficult to access percutaneously, since access to the critical midline pain pathways is blocked by the fibrous attachments in the epidural region at the C2-C3 level. A new surgical approach engineered by C.M. Schade, M.D., Ph.D., P.E. using cephaled electrode placement of round percutaneous leads under C1-C2-C3 has circumvented this barrier and evaded the damaging stresses of cervical rotation and flexion.

PHOTOS BY STEVE GALLEGOS, LONESTAR PHOTOGRAPHY STUDIOS, 214-452-7780

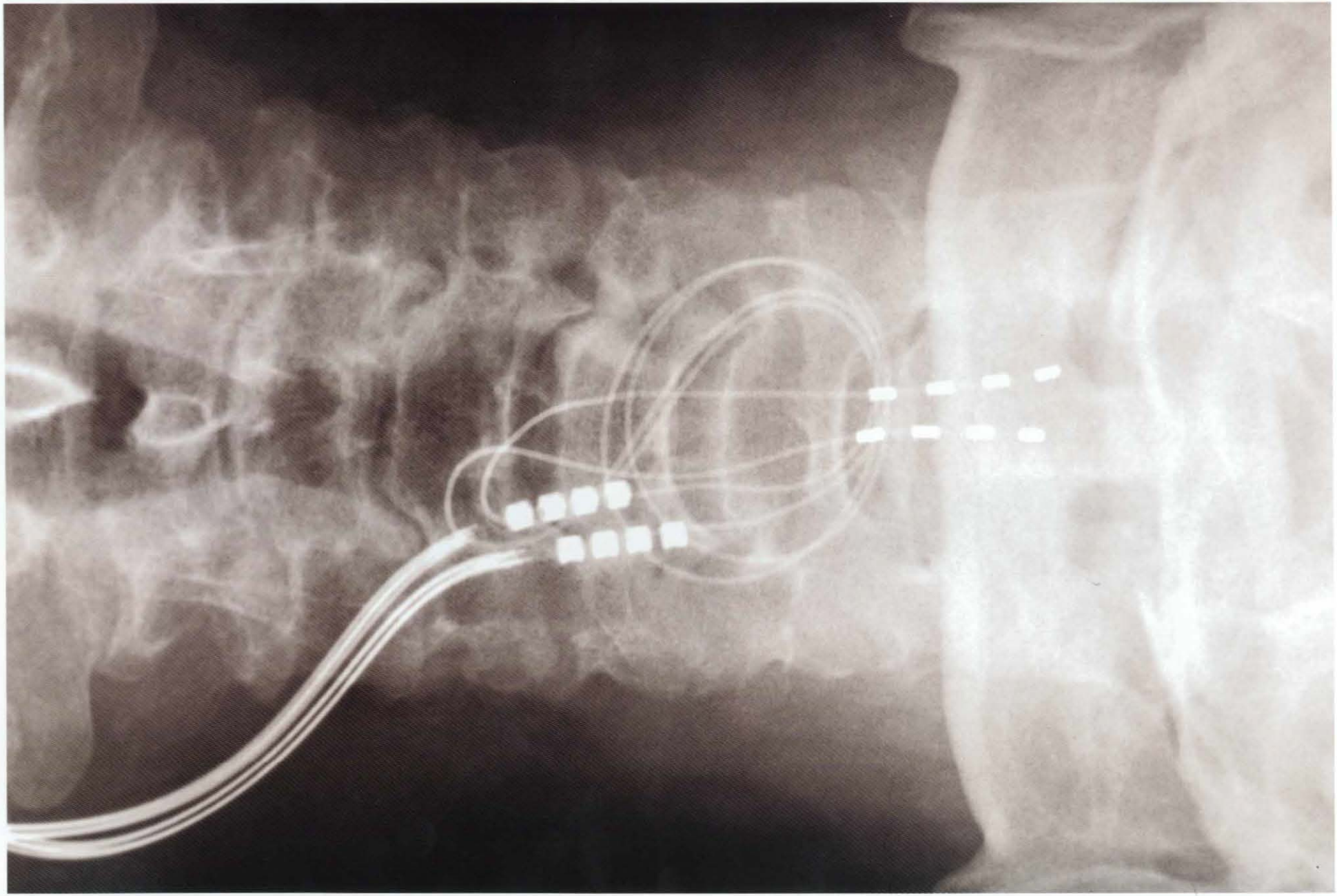

PHOTOS BY STEVE GALLEGOS, LONESTAR PHOTOGRAPHY STUDIOS, 214-452-7780



Brent C. Morgan, M.D.



C.M. Schade, M.D., Ph.D., P.E.

PHOTOS BY STEVE GALLEGOS, LONESTAR PHOTOGRAPHY STUDIOS, 214-452-7780

term. Pioneering efforts a decade ago by neurosurgeon Giancarlo Barolat, M.D., to address occipital or neck pain by introducing electrodes caudally under the arch of C1 and C2 successfully achieved paresthesia coverage of the painful region in about 80 percent of patients, but his cases were fraught with electrode breakage problems related to the extreme motion mechanics of the upper spine. Since nearly 50 percent of flexion and extension occurs at occiput-C1 and 50 percent of rotation at C1-C2, flat paddle lamitrodes, which were held firmly in position by post-surgical scarring, were vulnerable to malfunction and eventual breakage. Subsequent attempts to approach from under C3 going cephaled to C1-C2 with paddle leads met with slightly better success, but the paddle electrodes still tended to fail over time.

The neck neurological "sweet spot" first identified by Dr. Barolat is difficult to access percutaneously, since access to the critical midline pain pathways is blocked by the fibrous attachments in the epidural region at the C2-C3 level. A new surgical approach engineered by C.M. Schade, M.D., Ph.D., P.E., using cephaled electrode placement of round percutaneous leads under C1-C2-C3 has circumvented this barrier and evaded the damaging stresses of cervical rotation and flexion.

For patients with midline neck pain or occipital headaches there have historically been few effective options for pain relief.

We expect this technique to provide lasting results for chronic pain patients who suffer from cervical pain or occipital headaches and do not respond adequately to other methods of pain management. I believe that this population represents a significant proportion of all cervical pain patients.

—Brent C. Morgan, M.D.

Dr. Schade, who is a member of the medical staff at Vista Hospital of Dallas and a senior medical consultant with Medtronics Neurological, Inc., partnered with neurosurgeon Jay Law, M.D., at the Colorado

Neurological Institute in some of the earliest studies of SCS in low back pain. He has been involved in Pain Medicine for nearly 30 years, and, with an electrical engineering and computer science background, has been able to make unique contributions to the field. He is board-certified in anesthesiology and certified by four different boards in pain medicine, and is a past president and current board member of the Texas Pain Society. Dr. Schade has been performing spinal cord implants for 16 years.

Dr. Schade, who is a member of the medical staff at Vista Hospital of Dallas and a senior medical consultant with Medtronics Neurological, Inc., partnered with neurosurgeon Jay Law, M.D., at the Colorado Neurological Institute in some of the earliest studies of SCS in low back pain. He has been involved in pain medicine for nearly 30 years, and, with an electrical engineering and computer science background, has been able to make unique contributions to the field. He is board-certified in anesthesiology and certified by four different boards in pain medicine, and is a past president and current board member of the Texas Pain Society. Dr. Schade has been performing spinal cord implants for 16 years.

Now, Dr. Schade works in close concert with neurosurgeon Brent C. Morgan, M.D., to perform a modified version of the Barolat technique, in which two percutaneous quadripolar electrode leads are implanted, one on either side of the electrophysiologic midline. This new approach requires full surgical exposure and dissection under direct visualization of the C1-C3 region. The electrodes are placed under general anesthesia with the assistance of a spinal cord monitoring specialist and using a Mayfield head holder to immobilize the patient's head and cervical spine.

The round electrodes are anchored to the posterior spinous processes and, because their shape allows some movement, the problem of breakage appears to have been resolved. In the surgeries performed to date using this specialized technique, stimulation-induced paresthesia coverage of painful areas in the back of the head, neck, upper shoulders and arms has been achieved.

"A large number of patients have not experienced relief with a percutaneously implanted stimulator because the percutaneous approach does not provide access to this critically important C1-2 area of the spinal cord," notes Dr. Morgan. "We expect this technique to provide lasting results for chronic pain patients who suffer from cervical pain or occipital headaches, and do not respond adequately to other methods of pain management. I believe that this population represents a significant proportion of all cervical pain patients."

Dr. Morgan is a board-certified neurosurgeon who trained at the University of Maryland 11 years ago, and has been implanting spinal cord stimulators since his residency training in neurosurgery. He is also a member of the medical staff at Vista Hospital of Dallas.

Patients are carefully selected for candidacy according to the distribution of their pain. Additionally, appropriate patients have no other correctable source of pain, and have had a positive response with previous percutaneous trial stimulation. During the trial stimulation most patients remain in the hospital for a day or two after the trial stimulator is activated, during which time they document their pain level with SCS on and off in a journal and receive individualized training and informational booklets about the proper use of the pain stimulator.

According to Dr. Morgan, "Until recently, the importance of the C1-C2 area has been overlooked. We have gained a new understanding of its role in the management of difficult-to-treat chronic pain syndromes that are not alleviated by surgery or other conventional methods. Although more follow-up data must be accumulated to fully evaluate the long-term effectiveness of this procedure, patients who have been implanted using this technique have now experienced sustained pain relief for more than 12 months. We find that result to be very exciting and promising for the growing numbers of patients who seek relief from chronic neck and occipital headache pain."

Nearly 100 million Americans suffer from chronic pain, and over half are partially or totally disabled. Patients spend more than $100 billion each year to manage chronic pain, and many still do not receive adequate treatment or pain relief. In the case of chronic intractable occipital headache or midline neck pain, which can be difficult to control with other methods, highly advanced technologies and refined surgical techniques such as the new approach used at Vista Hospital of Dallas may be the only realistic opportunity for significant lasting relief.

Vista Hospital of Dallas is an acute care hospital specializing in spine and bariatric surgeries, outpatient orthopedics and pain management. Vista Hospital has evolved as a center of excellence for spinal cord stimulation and focuses significant resources on the needs of chronic pain patients. The state-of-the-art radiology department includes a sophisticated spiral CT scanner and has 24-hour neuroradiologist coverage. Vista's in-house team includes full-time hospitalists who provide around-the-clock coverage 365 days a year, making rounds, evaluating patients and consulting with the surgeon, if necessary. Administrator and CNO Penny Range, R.N., has assembled a specially tailored surgical and nursing staff to support SCS patients. Vista provides convenient accommodations for the families of surgical patients, who come from a wide geographical area.

For more information about Vista Hospital of Dallas or spinal cord stimulation for the management of chronic pain, call the Vista Physician Referral Call Center at (972) 487-2409. ■